

Includes the winning cases of the
**IPS e.max®
SMILE AWARD
2016**



REFLECT

3/16

Efficient and predictable

Combining universal adhesive and bulk-fill composite

Enhanced gingival esthetics for complete dentures

Optimizing complete dentures with an innovative veneering material

Digitally designed and meticulously implemented

All-ceramic restorations in the upper and lower jaw


ivoclar
vivadent
passion vision innovation

Digitally designed and meticulously implemented



All-ceramic restorations in the upper and lower jaw after the loss of occlusal vertical dimension
Prof. Dr Petra Gierthmühlen, Dusseldorf, and Udo Plaster, Nuremberg/Germany

IPS e.max Smile Award 2016: The winning entry in the “Europe, Middle East, Africa” category describes the restorative treatment of a patient who presented with severely eroded teeth. A focused defect-oriented approach characterized this case. Digital techniques paired with accurate planning and meticulous implementation ensured the minimally invasive restoration of the worn tooth structure.

The problem of worn and eroded teeth is becoming more prevalent. The pathological loss of tooth substance can be produced by erosion (acid-related tooth damage), attrition (tooth-to-tooth wear) or abrasion (mechanical processes). In most cases a number of factors contribute to the clinical picture. Once the causes have been established, suitable therapeutic measures can be planned. In modern dentistry, the removal of considerable amounts of tooth structure for the preparation of a restoration is viewed very critically. A more appropriate solution is to find a minimally invasive or non-invasive way of restoring the teeth using adhesively bonded restorations. This type of approach is described on the basis of the following case study.

Pre-operative situation

When he consulted our practice, the patient complained about restricted chewing function and tooth hypersensitivity. In addition, he was dissatisfied with the appearance of his teeth. The dental examination revealed large carious lesions and various defective fillings. All the teeth showed severe signs of erosion (Fig. 1). Substantial loss of tooth structure was evident in the anterior teeth in particular. The analysis of the smile line revealed that the length-to-width ratio had been negatively affected. In the relaxed smiling position, the teeth were hardly visible. In addition, the discrepancy between the smile line and the midline was very pronounced.

The patient showed considerable loss of occlusal vertical dimension (OVD). A functional disorder (e.g. craniomandibular dysfunction) was not diagnosed. The aim of the extensive treatment was to reconstruct the proportions, function and esthetics of the teeth. Therefore, the occlusion needed to be redefined and the vertical dimension adjusted.

Creation of the mock-up

In order to obtain a sound basis for the treatment planning process, the Face Hunter scanner was used to produce a digitalized picture of the patient’s face. The three-dimensional view of the pre-operative situation offers an advantage over conventional photographs in that it enables the envisaged situation to be examined from different aspects thereby providing a realistic overall picture. A digital wax-up with heightened occlusal plane was created with the PlaneSystem®. In this step, the tooth positions, lengths, sizes and shapes were determined on the basis of functional and esthetic criteria. The “Digital Articulator” module was used to check the static and dynamic occlusion. The digitally calculated movement paths correlated with the guiding surfaces of the teeth. In the process, the extraoral esthetic parameters were also checked.



Video of the winning entry

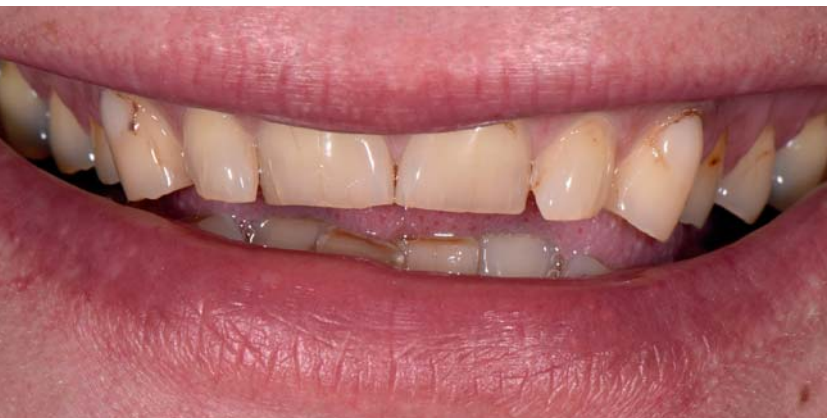

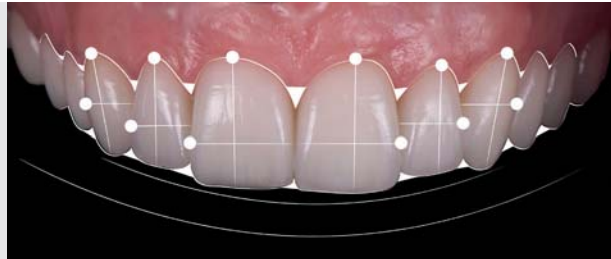
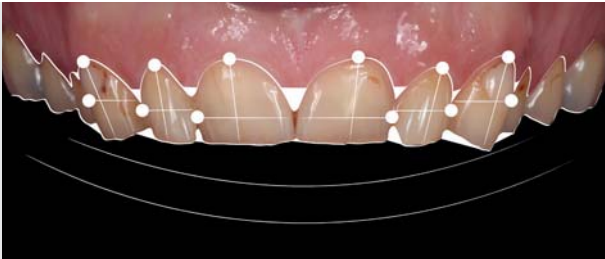
Fig. 1: Substantial loss of tooth structure, particularly in the anterior region

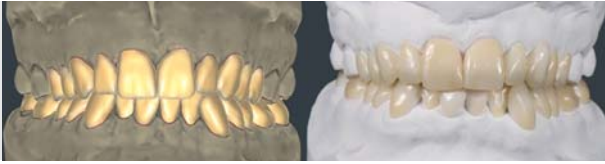

Fig. 2: A digital wax-up served as the basis for the creation of the PMMA mock-ups.

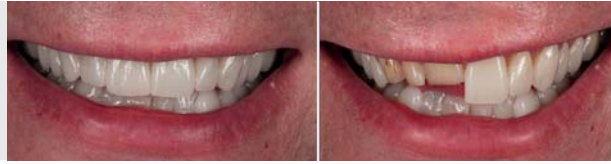

Fig. 3: Try-in of the mock-up in the mouth



Figs 4 and 5: Comparison of the esthetic analysis of the initial and the target situation

Features such as the bipupillary line, the smile line and the midline are important references for restoring facial harmony.

The segments designed with the Zirkonzahn software were used to construct a PMMA mock-up by means of CAD/CAM fabrication methods. The mock-up was tried in and deemed to be satisfactory in terms of its function and esthetics (Fig. 2). The new situation and the raised vertical dimension were accepted by the patient (Fig. 3). Therefore, the mock-up served as a template for the remainder of the treatment process (Figs 4 and 5). First, the digital design was used in the creation of the provisional restorations.

Tooth preparation and provisionalization

The restorative procedure involved the entire dental arch in both the upper and the lower jaw. The defective restorations were replaced and the teeth were prepared according to defect-oriented principles (Fig. 6). A minimally invasive approach was taken to prepare the upper anterior teeth for the crowns, the lower anterior teeth for the veneers and the molars for the crowns and onlays. The digitally designed final situation was superimposed on the prepared teeth to show the minimally invasive and additive character of the procedure. Conventional impressions were taken of the situation and sent to the dental laboratory (Fig. 7). Models were fabricated and digitized with a laboratory scanner (S600 Arti, Zirkonzahn). The preparation shade was determined in the laboratory in order to properly establish the individual tooth shades. This is particularly important when all-ceramics are used, since the preparation shade considerably influences the light-optical properties of these materials.

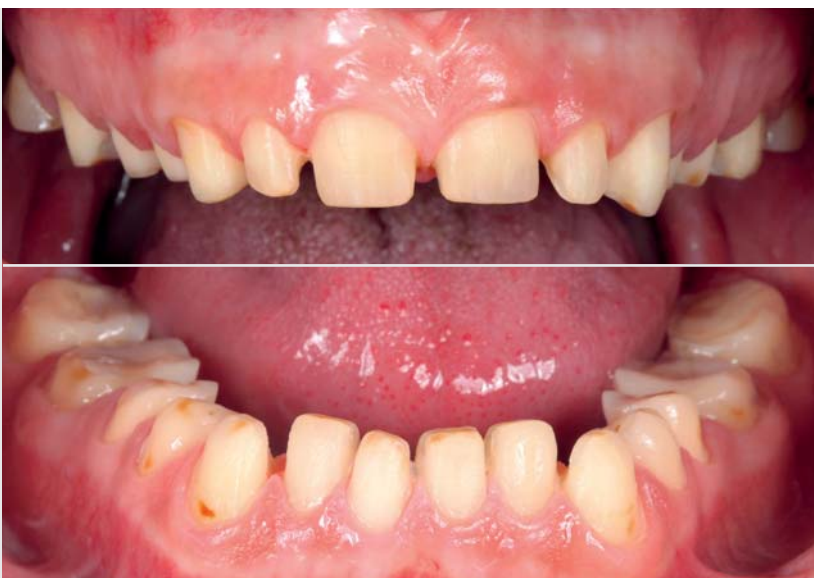

Fig. 6: Defect-oriented preparation of the upper and the lower jaw

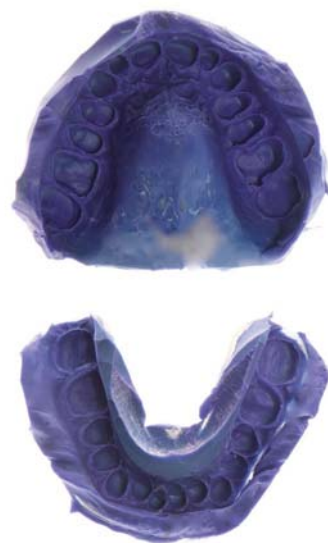

Fig. 7: Transfer of the situation by means of conventional impressions

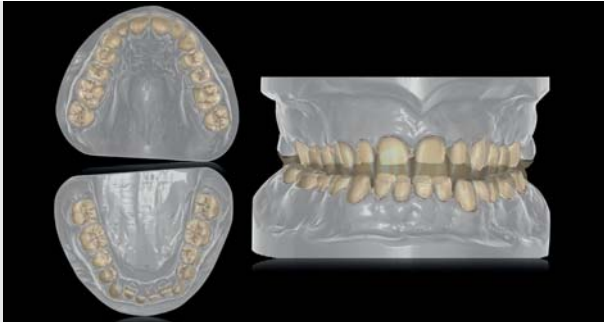


Fig. 8: The digital design of the mock-up for the provisional restorations

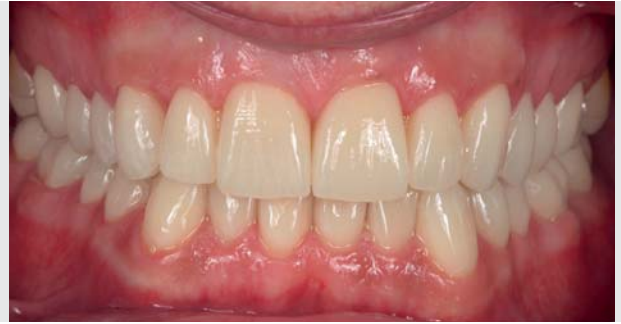

Fig. 9: The patient quickly became accustomed to the CAD/CAM manufactured provisionals.

The provisional restorations were fabricated using CAD/CAM technology. The crowns, veneers and onlays were adjusted to the prepared situation in the digital mock-up and then milled to full contour using a tooth-coloured PMMA material (Fig. 8). The fit of the restorations was checked on the model. Then the provisionals were polished and cemented in place with a temporary luting composite. The functional and esthetic factors were checked in the mouth. During the following eight weeks the patient was able to test the new situation and the raised vertical dimension (Fig. 9). At this stage, it was still possible to modify the restorations without any difficulty. However, the patient accustomed himself to the new vertical dimension very quickly and without any complications.

Fabrication of the all-ceramic restorations

The permanent restorations were fabricated with the help of the mock-up data. On the basis of the initial facial scan, the crowns, onlays and veneers were constructed in accordance with the mock-up (Fig. 10). Up to this part of the procedure, all the work had been done using digital means, without a conventional wax-up. This changed when the individual ceramic restorations, especially the veneers, were produced, since their esthetic design required considerable manual skill. In the present case, the plan was to obtain the functional and esthetic results with the press technique. For this purpose, the computer designed-restorations were machined in wax in a 5-axis milling unit (M5 Heavy Metal Milling Unit, Zirkonzahn) and subsequently pressed with the IPS e.max® lithium disilicate

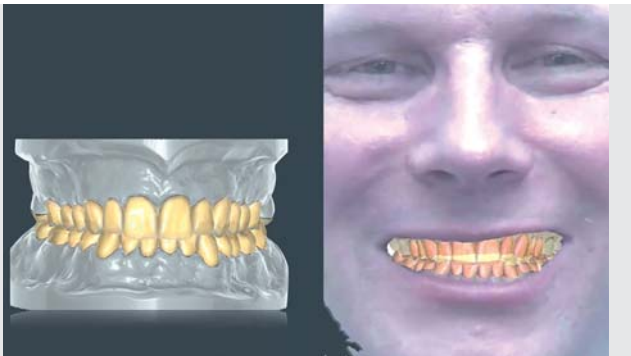

Fig. 10: Construction of the permanent restorations with the help of the initial facial scan and the mock-up



Fig. 11: The individual restorations were machined in wax, pressed with lithium disilicate glass-ceramic and subsequently finished.

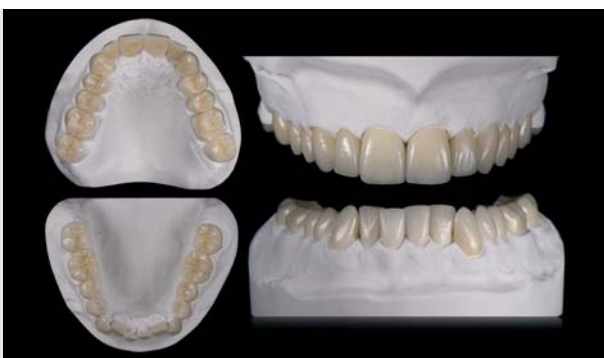

Fig. 12: The upper anterior teeth were cut back and then veneered. The veneers, the onlays and crowns for the molars were manufactured in monolithic form.

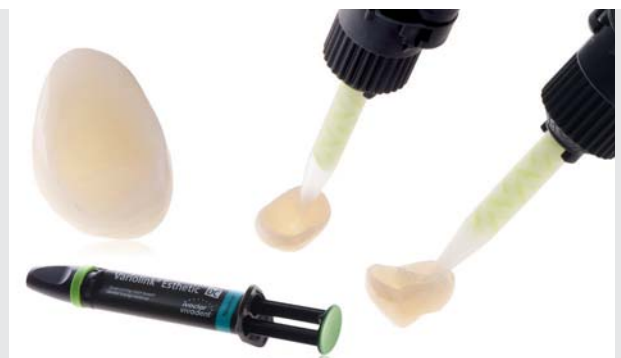
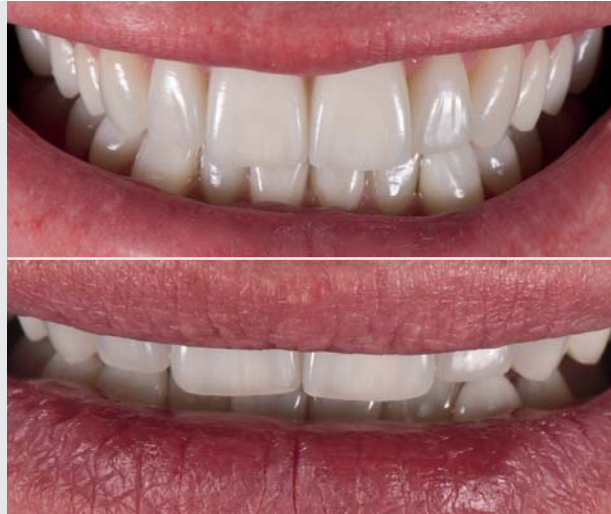
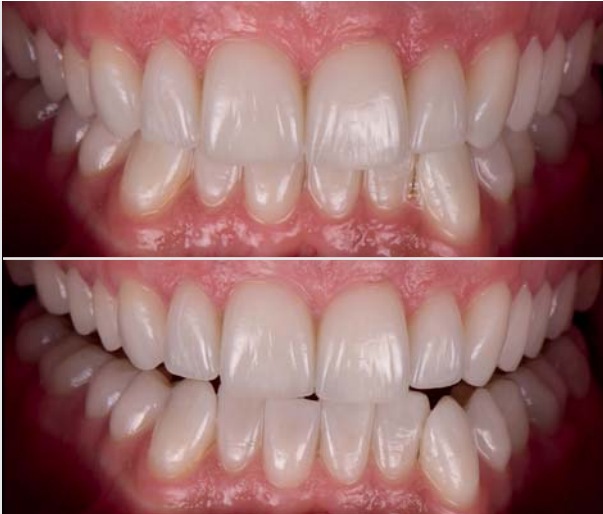Fig. 13: Preparation for the adhesive cementation



Figs 14 and 15: Photographic documentation of the result: The function and esthetics of the teeth completely fulfilled the requirements of the patient.

glass-ceramic (Fig. 11). The upper anterior restorations were cut back and then imparted with lifelike characteristics and play of colour. The crowns pressed with LT (Low Translucency) ingots in shade A1 were reduced and then the incisal areas were built up with veneering ceramic (IPS e.max Ceram). The pressed monolithic veneers for the lower anterior teeth as well as the onlays and the crowns for the posterior teeth showed adequate esthetics (ingot shade: MT A1). These monolithic restorations were polished to a high gloss and then individualized with stains (IPS e.max Shades/Essence & Glaze). On the

The restorations showed excellent marginal adaptation after their adhesive cementation. The transitions to the natural tooth structure were virtually invisible. In terms of their shape and function, the restorations fully corresponded to the result realized with the help of the provisional restorations (Figs 14 to 16). The permanent restorations were fabricated using CAD/CAM technology and the press technique. The thin, defect-oriented, individual restorations provided an esthetic, functional and reliable solution for restoring the dentition.

Conclusion

Digital technology – in the form of a face scanner for example – is of immense help in the treatment planning process. The minimally invasive approach used in this case is easy to implement with the help of CAD/CAM fabrication methods. The creation of a virtual wax-up, a CAD/CAM mock-up, provisionals and wax models for pressing the lithium disilicate restorations all contributed to achieving a predictable, esthetic, cost-effective and efficient result. The intraoral pictures taken three months after the treatment show the stable occlusion and the excellent condition of the periodontal tissue.



Fig. 16: The happy patient

model, the all-ceramic restorations looked very natural in terms of their colour and their shape (Fig. 12).

Adhesive cementation

In preparation for their placement the inner surfaces of the individual ceramic restorations were conditioned and etched with 4.9 per cent hydrofluoric acid (IPS® Ceramic Etching Gel) for 20 seconds. The clean prepared teeth were conditioned with the Syntac® Classic system, which comprises a primer, an adhesive and Heliobond. The lithium disilicate glass-ceramic restorations were adhesively bonded with a dual-curing luting composite (Variolink® Esthetic DC) in accordance with the instructions of the manufacturer (Fig. 13).



Contact details:

Prof. Dr Petra Gierthmühlen
Direktorin der Klinik
Poliklinik für Zahnärztliche Prothetik
Moorenstrasse 5, 40225 Dusseldorf
Germany
petra.gierthmuehlen@
med.uni-duesseldorf.de



Udo Plaster
Plaster Dental-Technik
Emilienstrasse 1
90489 Nuremberg
Germany
info@plasterdental.de

THIS WAS THE CEREMONY OF THE

IPS e.max[®] SMILE AWARD 2016

IN MADRID



Learn more
about the
winners

